ORIGINAL ARTICLE

DOI: 10.37047/jos.galenos.2026.2025-8-9

J Oncol Sci

# Vascular FDG Uptake on PET/CT in Patients Receiving Immune Checkpoint Inhibitors

Ali Kaan GÜREN[1], Kevser ÖKSÜZOĞLU[2], Erkam KOCAASLAN[1], Şerife ÇETİN[2], Taylan KAPLAN[3], Nazım Can DEMİRCAN[1], Murat SARI[1], Salih ÖZGÜVEN[2], Tunç ÖNEŞ[2], İbrahim Vedat BAYOĞLU[1], Osman KÖSTEK[1]

[1]Marmara University Faculty of Medicine, Department of Internal Medicine, Division of Medical Oncology, İstanbul, Türkiye
[2]Marmara University Faculty of Medicine, Department of Nuclear Medicine, İstanbul, Türkiye
[3]Marmara University Faculty of Medicine, Department of Internal Medicine, Division of Rheumatology, İstanbul, Türkiye

## ABSTRACT

**Objective:** Numerous drug-related adverse effects are difficult to distinguish because they emerge concurrently with disease progression. Aside from case reports and case reviews, there is a paucity of publications providing detailed analyses of immune checkpoint inhibitors (ICIs) in relation to increased vascular FDG Uptake on positron emission tomography/computed tomography (PET/CT).

**Material and Methods:** The study comprised patients with histopathologically diagnosed cancer who were treated with ICIs. We analysed pre- and post-treatment PET/CT images to calculate the PET vascular activity score (PETVAS) for 15 vascular areas. We specifically examined patients with greater uptake compared with baseline. Patients with non-small cell lung cancer (NSCLC) were categorised based on an increase in uptake; progression-free survival (PFS) and overall survival (OS) were compared.

**Results:** One hundred forty eight patients were included in the study. A total of 482 PET/CT images were examined. Patients received five different ICIs across 13 cancer types. Ten (6.7%) patients exhibited increased 18F-fluorodeoxyglucose (FDG) uptake relative to pretreatment. Two of them (1.3%) had grade 2 or higher uptake. Among 68 NSCLC patients, higher uptake did not significantly affect PFS or OS (p=0.73 for PFS and p=0.37 for OS; both p>0.05).

**Conclusion:** Clinical and biochemical manifestations of underlying malignancy may obscure ICI-related arteritis. In patients presenting with unexplained constitutional symptoms and elevated acute-phase reactants, the PETVAS score may support the identification of clinically relevant vascular FDG uptake and help guide further diagnostic evaluation.

**Keywords:** Immune checkpoint inhibitors; immune-related adverse events; arteritis; ICI related arteritis; PETVAS score

## INTRODUCTION

Immune checkpoint inhibitors (ICIs) are monoclonal antibodies structured as immunoglobulin G1 and immunoglobulin G4, employed in the treatment of various cancers by targeting specific molecules, including programmed cell death receptor-1 (PD-1), programmed cell death ligand-1 (PD-L1), and cytotoxic T lymphocyte-associated antigen-4 (CTLA-4).[1] Currently, they are utilised independently, in conjunction with traditional chemotherapies, or in combination with one another (against PD-1 or anti PDL-1 and CTLA-4) for the treatment of various malignancies.[2] Alongside offering considerable survival benefits in numerous cancer types, numerous immune-related adverse events (irAEs) such as pneumonitis, colitis, hepatitis, hypophysitis, thyroiditis, nephritis, and rash have been documented.[3,4] In addition to these clearly delineated irAEs, numerous case reports indicate that these medications can induce vasculitis with diverse presentations, encompassing both large-vessel vasculitis and anti-neutrophil cytoplasmic antibody (ANCA)-associated vasculitis. Nonetheless, there is no definitive consensus about the mechanism of ICI-related vasculitis.[5]

**Correspondence:** Ali Kaan GÜREN MD;
Marmara University Faculty of Medicine, Department of Internal Medicine, Division of Medical Oncology, İstanbul, Türkiye

**E-mail:** alikaanguren@gmail.com

**ORCID ID:** orcid.org/0000-0002-3562-5006

**Received:** 26.08.2025 **Accepted:** 08.03.2026 **Epub:** 12.03.2026

**Cite this article as:** Güren AK, Öksüzoğlu K, Kocaaslan E, et al. Vascular FDG uptake on PET/CT in patients receiving immune checkpoint inhibitors. J Oncol Sci. [Epub Ahead of Print]

Available at journalofoncology.org

*©Copyright 2026 The Author(s). Published by Galenos Publishing House on behalf of Turkish Society of Medical Oncology.*
*Licensed under a Creative Commons Attribution-NonCommercial-NoDerivatives 4.0 (CC BY-NC-ND) International License.*

Arteritis encompasses a diverse array of disorders characterised by inflammation of the vessel wall. While it results in varying clinical manifestations depending on the affected organ, constitutional symptoms, such as malaise and fatigue, are present in nearly all cases of arteritis. Diagnosis is based on laboratory findings, clinical observations, imaging techniques, and, where feasible, histological analysis.[6,7] Laboratory results and systemic symptoms resemble the clinical manifestations observed in cancer patients, particularly during the metastatic phase. In cancer patients, The common constitutional symptoms such as malaise, fatigue, muscle pain, and elevated acute-phase reactants are often associated with the primary disease itself. Many side effects develop concurrently with disease progression and therefore cannot be clearly defined.

Positron emission tomography-computed tomography (PET/CT) has long been used in the diagnosis and follow-up of arteritis.[8] The primary advantages encompass its non-invasive nature, early identification of inflammation, and concurrent visualization of multiple vascular regions.[9] The PET vascular activity score (PETVAS), calculated from 18F-fluorodeoxyglucose (FDG) uptake across 15 vascular areas, has been shown to be effective in diagnosing and monitoring large artery vasculitis. Despite debates over its sensitivity and specificity, extensive research exists on its application in patients diagnosed with and monitored for arteritis.[10-12]

Although the diagnosis of arteritis is established through a combination of clinical, laboratory, radiological, and histopathological findings, documenting this retrospectively, particularly in a cohort of cancer patients, is challenging. In this context, the present study aims to examine the frequency of increased FDG uptake — which may assist in the diagnosis of arteritis — in patients receiving ICIs, and to evaluate the association between this increased FDG uptake and survival in patients with non-small cell lung cancer (NSCLC).

## MATERIAL AND METHODS

### Study Population

Patients who received treatment at the Marmara University Pendik Training and Research Hospital, Medical Oncology Clinic between January 1, 2018, and December 31, 2023 were included in the study. They had to have been diagnosed with cancer by histopathological examination and to have received any ICI as part of their treatment. Patients treated with ICI for less than 3 months; patients with a diagnosis of rheumatologic disease; patients with chronic arterial disease (including atherosclerosis); patients receiving statins for any indication; and patients who received radiotherapy within the last 1 year were excluded from the study.

### Data Collection and Study Design

The patients' data were retrospectively analysed using patient files and the hospital electronic information system. For PET/CT imaging, scans were performed in 3D mode from the head to below the knee. The acquired images were reconstructed in cross-sectional, coronal, and sagittal planes. A low-dose CT scan was performed to provide attenuation correction and anatomical orientation. Imaging was performed one hour after FDG injection. Four independent nuclear medicine physicians interpreted the images, unaware of the clinical data. A total of 15 arterial regions were evaluated: ascending aorta, aortic arch, descending thoracic aorta, abdominal aorta, innominate artery, carotid arteries, subclavian arteries, axillary arteries, iliac arteries, and femoral arteries. PETVAS was calculated. Arterial regions were graded according to FDG uptake on a 0-3 scale: Grade 0 — no uptake; Grade 1 — less uptake than the liver; Grade 2 — uptake equal to the liver; Grade 3 — greater uptake than the liver. Patients' treatment responses were evaluated according to the Response Evaluation Criteria in Solid Tumours version 1.1.

PET/CTs performed within 1 month before the ICIs' start date, at 3 months post-treatment, and at 6 months, 1 year, 2 years, and 3 years (for patients who continued treatment) were analysed, and PETVAS scores were calculated. Since the largest patient group comprised patients with NSCLC, this group was analysed in more detail with respect to the relationship between PETVAS score and survival. All patients in the NSCLC group were at the metastatic stage and had received at least one line of chemotherapy. All patients had received ICI alone in the 2$^{nd}$ or subsequent lines. Patients with no increase in FDG uptake after treatment were assigned to Group 1, and those with increased uptake were assigned to Group 2. Progression-free survival (PFS) and overall survival (OS) were compared between groups.

### Statistical Analysis

All statistical analyses were performed using SPSS version 22.0 (IBM Corp.). PFS was calculated as the time in months from the first treatment dose to disease progression, death (if the patient died during treatment), or the day of the last visit (if the patient was still receiving treatment). OS was calculated as the time in months from the first treatment dose to the date of death or to the date of the last visit, if the patient was still alive. Categorical variables were analyzed using the chi-square test. 95% confidence intervals (CIs) were calculated using the Brookmeyer and Crowley method. When the study data were evaluated, the conformity of the parameters to a normal distribution was assessed by the Shapiro-Wilk test. An

independent-samples t-test was used to compare normally distributed parameters, and the Mann-Whitney U test was used to compare non-normally distributed parameters. Survival differences between the groups were compared using the log-rank test. Significance was evaluated at the $p<0.05$ level.

### Ethics Statements

This study was conducted in accordance with the principles of the Declaration of Helsinki. Approval was granted by Marmara University Faculty of Medicine, İstanbul, Türkiye, number: 09.2024.911, date: 19.07.2024.

## Results

We evaluated 207 patients who received ICIs. Thirty four patients were excluded because they received ICIs for less than three months; 16 patients were excluded because they did not have baseline or control PET/CT scans; and 9 patients were excluded because the data were incomplete. A total of 148 participants took part in the trial. A total of 482 PET/CT scans were assessed: 148 prior to therapy, 148 at three months, 102 at six months, 44 at one year, 22 at two years, and 18 at three years.

The average age of the patients was 63.2 years, with a range from 31 to 88 years. There were 113 male and 35 female patients. The patients were diagnosed with SCLC, NSCLC, renal cell carcinoma (RCC), malignant melanoma, bladder carcinoma, hepatocellular carcinoma, esophageal carcinoma, head and neck cancers, breast carcinoma, endometrial carcinoma, rectal carcinoma, and Merkel cell carcinoma. One hundred forty six patients presented with metastatic disease, whereas 2 patients presented with stage 3 disease. We used nivolumab, the combination of nivolumab and ipilimumab, atezolizumab, pembrolizumab, and avelumab as ICIs. Table 1 delineates the characteristics of the patients and the distribution of these characteristics.

A total of 148 patients received ICI treatment. A total of 136 patients received immunotherapy alone, while 12 patients received treatment in combination with chemotherapy. Among 136 patients, 13 had received tyrosine kinase inhibitors (patients diagnosed with hepatocellular carcinoma and RCC). In previous series, chemotherapy was used in 123 patients. Chemotherapy agents received were cisplatin, carboplatin, gemcitabine, pemetrexed, docetaxel, paclitaxel, vinorelbine, 5-fluorouracil, irinotecan, and oxaliplatin.

Pre-treatment PET/CT scans of 128 patients showed no increased FDG uptake in any region. Increased uptake with a total score of 1 or more was observed in 20 patients. Scores of patients with uptake ranged from 1 to 8, and none of the patients had an uptake of 2 points or more in any region. Five patients had uptake in 1 region, 10 patients had uptake in 2 regions, 3 patients had uptake in 3 regions, 1 patient had uptake in 7 regions, and 1 patient had uptake in 8 regions.

On post-treatment PET/CTs, no change was observed in 120 (81%) patients who had no uptake at baseline. On PET/CT, among 20 (13.5%) patients who had uptake at baseline, uptake continued at the same level in 9 (6%) patients, decreased but persisted in 5 (3.4%) patients, disappeared completely in 4 (2.6%) patients, and increased in 2 (1.3%) patients. In 8 (5.4%) patients who initially had no uptake, increased uptake was observed after treatment. In total, 10 (6.7%) patients showed increased uptake compared to pre-treatment PET/CT. In 2 of these patients (1.3%), 2 or more uptakes were detected in any region. These findings are summarised in Table 2.

**TABLE 1: Basic characteristics of patients.**

| | Total patiens (n=148) |
|---|---|
| Age (minimum-maximum) | 63.2 (31-88) |
| **Gender (%)** | |
| Male | 113 (76.4) |
| Female | 35 (23.6) |
| **Types of cancer (%)** | |
| Lung cancer (LC) | 79 (53.3) |
| Small cell LC | 7 (4.7) |
| Non-small cell LC | 72 (48.6) |
| Renal cell cancer | 29 (19.5) |
| Malign melanoma | 14 (9.4) |
| Bladder cancer | 7 (4.7) |
| Hepatocellular cancer | 4 (2.7) |
| Esophageal cancer | 4 (2.7) |
| Mesothelioma | 4 (2.7) |
| Head and neck cancers | 3 (2) |
| Breast cancer | 1 (0.6) |
| Endometrial carcinoma | 1 (0.6) |
| Rectal cancer | 1 (0.6) |
| Merkel cell carcinoma | 1 (0.6) |
| **Stage (%)** | |
| Metastatic stage | 146 (98.6) |
| Non-metastatic stage | 2 (1.3) |
| **ICIs (%)** | |
| Nivolumab | 120 (81) |
| Nivolumab + Ipilimumab | 5 (3.3) |
| Atezolizumab | 11 (7.4) |
| Pembrolizumab | 8 (5.4) |
| Avelumab | 4 (2.7) |

ICIs: Immune checkpoint inhibitors.

Of the 10 patients with increased involvement, 5 had NSCLC, 2 had RCC, 2 had bladder cancer, and 1 had SCLC. Five patients received nivolumab, 2 received pembrolizumab, 2 received atezolizumab, and 1 received avelumab; these findings are shown in Table 3.

One of the patients with grade 2 or higher uptake, a 68-year-old male with SLCL, was treated with carboplatin, etoposide, and atezolizumab for 3 months, and PET/CT showed increased uptake in 5 regions. Grade 3 uptake was observed in the left subclavian artery, whereas grade 2 uptake was observed in the right subclavian and right axillary arteries. In addition, grade 1 uptake was observed in the left axillary and right brachiocephalic arteries. Figure 1 displays the patient's pre- and post-treatment PET/C scans. Another patient exhibiting increased uptake was a 65-year-old male with NSCLC. The patient received 5 lines of conventional chemotherapy, followed by single-agent nivolumab as 6th-line therapy. PET/CT at the 6th month of treatment showed almost complete regression, while PET/CT at the 9th month of treatment showed grade 2 involvement in the left carotid and right brachiocephalic arteries, and grade 1 involvement in the right carotid and left brachiocephalic arteries. No increased involvement was observed in any of the previous scans. Table 4 summarises the involved regions and the maximum scores for the remaining patients. Increased involvement was found in 5 patients at the 3rd month follow-up, in 3 patients at the 6th month follow-up, and in 2 patients at the 9th month follow-up. The mean time to the development of uptake was 5.1 months.

**TABLE 2: The distribution of patients before and after treatment according to PETVAS score.**

| | Total patients (n=148) |
|---|---|
| **Pre-treatment (%)** | |
| PETVAS =0 | 128 (86.4) |
| PETVAS ≥1 | 20 (13.5) |
| **Post-treatment (%)** | |
| Always negative | 120 (81) |
| Stable while positive | 9 (6) |
| Decreasing while positive | 9 (6) |
| Increasing while positive | 2 (1.3) |
| Increasing while negative | 8 (5.4) |
| Total increasing | 10 (6.7) |
| ≥2 in any artery | 2 (1.3) |

PETVAS: Positron emission tomography vascular activity score.

**TABLE 3: Characteristics of patients with increased uptake, ICIs used and time until increased uptake.**

| | Total patiens (n=10) |
|---|---|
| **Types of cancer (%)** | |
| Non-small cell lung cancer (LC) | 5 (50) |
| Renal cell cancer | 2 (20) |
| Bladder cancer | 2 (20) |
| Small cell LC | 1 (10) |
| **Stage (%)** | |
| Metastatic stage | 10 (100) |
| **ICIs (%)** | |
| Nivolumab | 5 (50) |
| Pembrolizumab | 2 (20) |
| Atezolizumab | 2 (20) |
| Avelumab | 1 (10) |
| **Time until increased uptake (%)** | |
| 3 months | 5 (50) |
| 6 months | 3 (30) |
| 9 months | 2 (20) |

ICIs: Immune checkpoint inhibitors.

Seventy-two patients with NSCLC received immunotherapy treatment. Survival data for 69 patients were calculated. While 64 patients (Group 1) had no significant increase in PET/CT uptake after treatment, 5 patients (Group 2) had increased uptake compared with pre-treatment PET/CTs. Table 5 describes the main characteristics of the groups. Median PFS was 6.26 months (95% CI: 5.21-7.32) in Group 1; 7.2 months (95% CI: 1.92-12.47) in Group 2; and 6.33 months (95% CI: 5.29-7.37) in all patients. When the groups were compared, the p-value was 0.73, indicating that the difference was not statistically significant (p>0.05). Median OS was 9.40 months (95% CI: 8.13-10.67) for Group 1, 11.4 months (95% CI: 5.56-17.23) for Group 2, and 9.55 months (95% CI: 8.30-10.79) overall. When the groups were compared, the p-value was 0.37, which is not statistically significant (p>0.05).

## Discussion

ICIs were associated with increased FDG uptake of at least grade 1 in 6.7% of our patients and of grade 2 or higher in 1.3%. This increased uptake was evaluated specifically in NSCLC patients; no difference in survival was observed between those with and without increased uptake. Furthermore, during the follow-up period, none of our patients were suspected of having arteritis; the data were analyzed retrospectively.

There are many comprehensive studies demonstrating that patients with irAEs who receive ICIs have longer survival compared to those without irAEs.[13,14] Accordingly, we grouped patients diagnosed with NSCLC into two groups: those with an increase in PETVAS score after ICIs and those without. When we compared the PFS and OS of the two groups, there was a numerical difference between them, but it was not

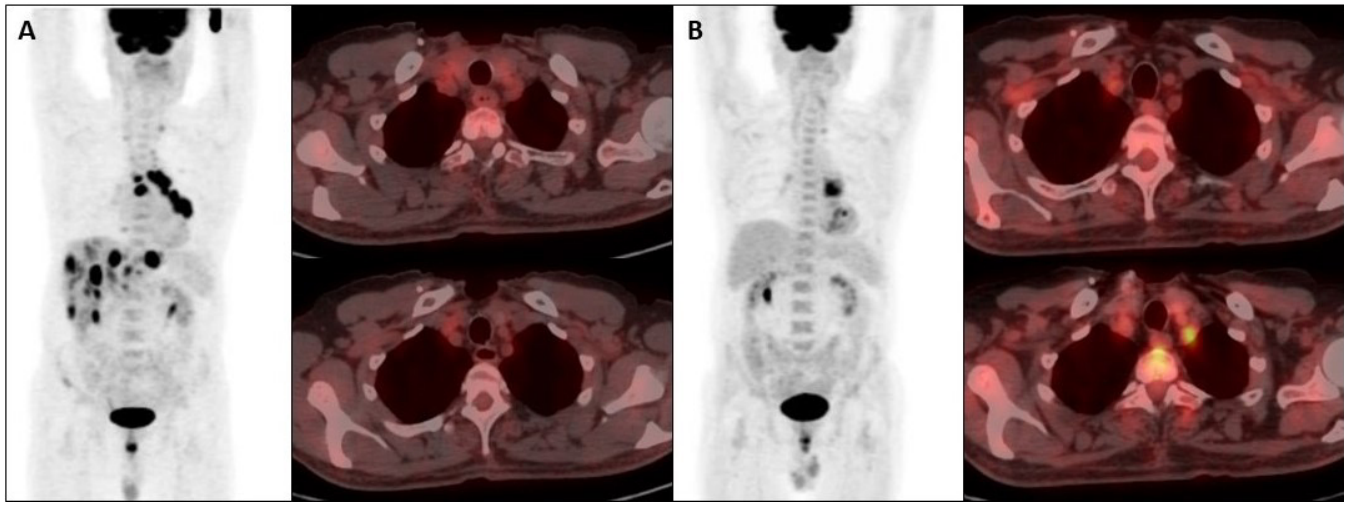


**FIGURE 1:** A) PET/CT sections before treatment B) PET/CT sections after treatment.

*PET: Positron emission tomography; CT: Computed tomography.*

**TABLE 4: Distribution of patients with increased PETVAS score according to the number of involved arteries and PETVAS score.**

| Number of patients (%) | Number of arteries | Maximum score | Total score |
|---|---|---|---|
| 1 (10) | 1 | 1 | 1 |
| 4 (40) | 2 | 1 | 2 |
| 1 (10) | 3 | 1 | 3 |
| 2 (20) | 4 | 1 | 4 |
| 1 (10) | 3 | 2 | 5 |
| 1 (10) | 5 | 3 | 9 |

PETVAS: Positron emission tomography vascular activity score.

statistically significant. Considering the insufficient number of patients and the unequal distribution of patients among the groups, we believe larger studies are needed to ensure statistical reliability.

In the review by Daxini et al.[5], the median time from the initiation of treatment until vasculitis developed was 3 months.[6] Of our two patients with grade 2 or higher uptake, one had increased uptake at the 3rd-month follow-up, whereas the other had increased uptake on PET/CT performed at the 9th month. The mean time course for all patients with increased uptake was 5.1 months, indicating that increased uptake may occur at a later stage than reported in previous studies.

ICI-associated vasculitis may lead to heterogeneous involvement ranging from cerebral vasculitis to ANCA-associated vasculitis, from systemic vasculitis to large vessel vasculitis.[15-18] Although tissue biopsy is the gold standard for diagnosing vasculitis, it is not always possible in large-vessel vasculitis. In the diagnosis of large vessel vasculitis, magnetic resonance imaging and PET/CT come to the forefront in patients in whom biopsy cannot be performed and are accepted as the standard approach.[19] In our study, we examined large-vessel involvement because we evaluated only PET/CT scans from patients assessed retrospectively, in whom vasculitis was not suspected and was therefore not adequately investigated. The PETVAS score, which is used to define, grade, and standardise arterial involvement status, indicated arterial involvement that varied according to the timing of treatment initiation. Because that we frequently use PET/CT in disease follow-up, we consider that the evaluation of the PETVAS score by nuclear medicine specialists in patients with suspected vasculitis, without the need for additional examinations and costs will contribute to the diagnosis and follow-up.

ICIs has been primarily administered in the treatment of malignant melanoma.[20] Therefore, like many irAEs, ICI-related vasculitis was first observed in patients diagnosed with malignant melanoma.[6] As ICIs began to be administered in other malignancies, ICIs-related vasculitis was reported in cancer types such as lung cancer and RCC.[4] Our study revealed increased FDG uptake in patients with NSCLC, SCLC, RCC, and bladder cancer. In addition to ICIs used in the first reported cases, such as nivolumab, ipilimumab, and pembrolizumab, increased involvement was also found in our patients treated with atezolizumab and avelumab. Considering all of the above, we think that ICI-related vasculitis can be expected in all cancer patients treated with ICIs, regardless of the primary cancer and the type of ICI used.

PETVAS has emerged as a valuable tool for quantitatively assessing vascular FDG uptake and detecting vascular inflammation. Elevated PETVAS scores are generally associated with active arteritis and reflect increased metabolic activity due to inflammatory cell infiltration in the vessel

**TABLE 5: Baseline characteristics of patients with metastatic non-SCLC, medication used and PFS and OS times.**

| | Group 1 (n=64) | Group 2 (n=5) | Total patients (n=69) | p |
|---|---|---|---|---|
| Age (minimum-maximum) | 64.2 (42-82) | 67 (56-79) | 64.9 (42-82) | 0.23 |
| Gender (%) | | | | |
| Male | 54 (84.3) | 5 (100) | 59 (85.5) | 0.33 |
| Female | 10 (15.6) | 0 (0) | 10 (14.4) | |
| ICIs (%) | | | | |
| Nivolumab | 61 (95.3) | 4 (80) | 65 (94.2) | 0.15 |
| Pembrolizumab | 3 (4.6) | 1 (20) | 4 (5.7) | |
| PFS median (95% CI) | 6.26 (5.21-7.32) | 7.20 (1.92-12.47) | 6.33 (5.29-7.37) | 0.73 |
| OS median (95% CI) | 9.40 (8.13-10.67) | 11.4 (5.56-17.23) | 9.55 (8.30-10.79) | 0.37 |

SCLC: Small cell lung cancer; PFS: Progression-free survival; OS: Overall survival; CI: Confidence interval.

wall.[21] However, high PETVAS scores can also be observed in advanced age, atherosclerotic plaques, and systemic inflammation.[12] In our study, patients were categorized as having increased PETVAS uptake if uptake increased compared with baseline imaging; patients with persistent uptake at baseline without an increase were not included in the increased FDG uptake group.

### Study Limitations

The absence of a control group of cancer patients not treated with ICIs is a key limitation. It prevents us from determining whether the observed vascular FDG uptake is attributable to ICI therapy itself or to other factors that are common in advanced cancer, such as atherosclerosis or systemic inflammation. Therefore, our findings suggest an association but cannot establish causality. Furthermore, we were unable to evaluate laboratory data because of missing values and discrepancies in acute-phase reactants caused by frequent intercurrent infectious conditions and acute pathologies. Detailed physical examination findings could not be documented because the systemic evaluations performed during patient examinations focused on the primary disease.

## Conclusion

Increased vascular FDG uptake may represent an underrecognized imaging finding in patients receiving ICIs. As ICIs are increasingly used across disease stages, such findings may be encountered more frequently in routine clinical practice. In patients with unexplained systemic symptoms and elevated inflammatory markers, PET-based vascular assessment using the PETVAS score may provide a practical tool to support clinical decision-making and guide further evaluation. These imaging findings may prompt consideration of immune-mediated arteritis in the appropriate clinical context.

### Ethics

**Ethics Committee Approval:** This study was conducted in accordance with the principles of the Declaration of Helsinki. Approval was granted by Marmara University Faculty of Medicine, İstanbul, Türkiye, number: 09.2024.911, date: 19.07.2024.

**Informed Consent:** Retrospective study.

### Footnotes

#### Authorship Contributions

Surgical and Medical Practices: A.K.G., K.Ö., N.C.D., M.S., S.Ö., T.Ö., İ.V.B., O.K., Concept: A.K.G., M.S., Design: A.K.G., E.K., T.K., T.Ö., İ.V.B., O.K., Data Collection or Processing: A.K.G., E.K., T.Ö., İ.V.B., Analysis or Interpretation: K.Ö., Ş.Ç., S.Ö., T.Ö., İ.V.B., O.K., Literature Search: Ş.Ç., T.K., İ.V.B., O.K., Writing: A.K.G., O.K.

**Conflict of Interest:** No conflict of interest was declared by the authors.

**Financial Disclosure:** The authors declared that this study received no financial support.

## References

1. Pavan A, Attili I, Pasello G, Guarneri V, Conte PF, Bonanno L. Immunotherapy in small-cell lung cancer: from molecular promises to clinical challenges. J Immunother Cancer. 2019;7(1):205. [Crossref] [PubMed] [PMC]
2. Shitara K, Ajani JA, Moehler M, et al. Nivolumab plus chemotherapy or ipilimumab in gastro-oesophageal cancer. Nature. 2022;603(7903):942-948. [Crossref] [PubMed] [PMC].
3. Naidoo J, Murphy C, Atkins MB, et al. Society for Immunotherapy of Cancer (SITC) consensus definitions for immune checkpoint inhibitor-associated immune-related adverse events (irAEs) terminology. J Immunother Cancer. 2023;11(3):e006398. [Crossref] [PubMed] [PMC]
4. Lee CM, Wang M, Rajkumar A, Calabrese C, Calabrese L. A scoping review of vasculitis as an immune-related adverse event from checkpoint inhibitor therapy of cancer: unraveling the complexities at the intersection of immunology and vascular pathology. Semin Arthritis Rheum. 2024;66:152440. [Crossref] [PubMed]
5. Daxini A, Cronin K, Sreih AG. Vasculitis associated with immune checkpoint inhibitors-a systematic review. Clin Rheumatol. 2018;37(9):2579-2584. [Crossref] [PubMed]
6. Saadoun D, Vautier M, Cacoub P. Medium- and large-vessel vasculitis. Circulation. 2021;143(3):267-282. [Crossref] [PubMed]

7. Maz M, Chung SA, Abril A, et al. 2021 American College of Rheumatology/vasculitis foundation guideline for the management of giant cell arteritis and takayasu arteritis. Arthritis Rheumatol. 2021;73(8):1349-1365. [Crossref] [PubMed] [PMC]
8. Salvarani C, Soriano A, Muratore F, Shoenfeld Y, Blockmans D. Is PET/CT essential in the diagnosis and follow-up of temporal arteritis? Autoimmun Rev. 2017;16(11):1125-1130. [Crossref] [PubMed]
9. Dejaco C, Ramiro S, Duftner C, et al. EULAR recommendations for the use of imaging in large vessel vasculitis in clinical practice. Ann Rheum Dis. 2018;77(5):636-643. [Crossref] [PubMed]
10. Galli E, Muratore F, Mancuso P, et al. The role of PET/CT in disease activity assessment in patients with large vessel vasculitis. Rheumatology (Oxford). 2022;61(12):4809-4816. [Crossref] [PubMed] [PMC]
11. Grayson PC, Alehashemi S, Bagheri AA, et al. $^{18}$F-fluorodeoxyglucose-positron emission tomography as an imaging biomarker in a prospective, longitudinal cohort of patients with large vessel vasculitis. Arthritis Rheumatol. 2018;70(3):439-449. [Crossref] [PubMed] [PMC]
12. Dashora HR, Rosenblum JS, Quinn KA, et al. Comparing semiquantitative and qualitative methods of vascular $^{18}$F-FDG PET activity measurement in large-vessel vasculitis. J Nucl Med. 2022;63(2):280-286. [Crossref] [PubMed] [PMC]
13. Zhang Q, Wang W, Yuan Q, et al. Correlation between immune-related adverse events and the efficacy of PD-1/PD-L1 inhibitors in the treatment of non-small cell lung cancer: systematic review and meta-analysis. Cancer Chemother Pharmacol. 2022;89(1):1-9. [Crossref] [PubMed] [PMC]
14. Zhou X, Yao Z, Yang H, Liang N, Zhang X, Zhang F. Are immune-related adverse events associated with the efficacy of immune checkpoint inhibitors in patients with cancer? A systematic review and meta-analysis. BMC Med. 2020;18(1):87. [Crossref] [PubMed] [PMC]
15. Läubli H, Balmelli C, Kaufmann L, et al. Influenza vaccination of cancer patients during PD-1 blockade induces serological protection but may raise the risk for immune-related adverse events. J Immunother Cancer. 2018;6(1):40. [Crossref] [PubMed] [PMC]
16. Laamech R, Terrec F, Emprou C, et al. Efficacy of plasmapheresis in nivolumab-associated ANCA glomerulonephritis: a case report and pathophysiology discussion. Case Rep Nephrol Dial. 2021;11(3):376-383. [Crossref] [PubMed] [PMC]
17. Betrains AE, Blockmans DE. Immune checkpoint inhibitor-associated polymyalgia rheumatica/giant cell arteritis occurring in a patient after treatment with nivolumab. J Clin Rheumatol. 2021;27(8S):S555-S556. [Crossref] [PubMed]
18. Kang A, Yuen M, Lee DJ. Nivolumab-induced systemic vasculitis. JAAD Case Rep. 2018;4(6):606-608. [Crossref] [PubMed] [PMC]
19. Dejaco C, Ramiro S, Bond M, et al. EULAR recommendations for the use of imaging in large vessel vasculitis in clinical practice: 2023 update. Ann Rheum Dis. 2024;83(6):741-751. [Crossref] [PubMed]
20. Larkin J, Chiarion-Sileni V, Gonzalez R, et al. Combined nivolumab and ipilimumab or monotherapy in untreated melanoma. N Engl J Med. 2015;373(1):23-34. Erratum in: N Engl J Med. 2018;379(22):2185. [Crossref] [PubMed] [PMC]
21. Kang F, Han Q, Zhou X, et al. Performance of the PET vascular activity score (PETVAS) for qualitative and quantitative assessment of inflammatory activity in Takayasu's arteritis patients. Eur J Nucl Med Mol Imaging. 2020;47(13):3107-3117. [Crossref] [PubMed]