CASE REPORT

DOI: 10.37047/jos.galenos.2026.2025-10-7

J Oncol Sci

Synchronous Adrenocortical Carcinoma, Renal Cell Carcinoma, and Mediastinal Mature Teratoma with Heterozygous Variants in SMARCA4, APC, and MYBP3: A Case Report

Ferit ASLAN[1], Burcu ERKILIÇ[2], Şeref Barbaros ARIK[3], Fisun ARDIÇ YÜKRÜK[4], Ersin ATABEY[5], Fatih YILDIZ[6], Hakan TABAN[1]

[1]Yüksek İhtisas Afiliated Medicalpark Ankara Hospital, Clinic of Medical Oncology, Ankara, Türkiye
[2]Yüksek İhtisas University Faculty of Medicine, Department of Internal Medicine, Ankara, Türkiye
[3]Yüksek İhtisas Afiliated Medicalpark Ankara Hospital, Clinic of Radiology, Ankara Türkiye
[4]University of Health Sciences Türkiye, Dr. Abdurrahman Yurtaslan Oncology Training and Research Hospital, Department of Pathology, Ankara, Türkiye
[5]Yüksek İhtisas Afiliated Medicalpark Ankara Hospital, Clinic of Urology, Ankara, Türkiye
[6]University of Health Sciences Türkiye, Dr. Abdurrahman Yurtaslan Oncology Training and Research Hospital, Department of Medical Oncology, Ankara, Türkiye

ABSTRACT

We describe an exceptionally rare case of a 46-year-old woman diagnosed with three synchronous primary tumors: adrenocortical carcinoma (ACC), renal cell carcinoma (RCC), and an anterior mediastinal mature teratoma. Cross-sectional imaging demonstrated distinct lesions of comparable size (each measuring 6-7 cm) in the right adrenal gland, right kidney, and the mediastinum. The patient underwent radical nephrectomy, adrenalectomy, and excision of the mediastinal mass. Histopathology confirmed clear cell RCC, ACC, and a mature teratoma without malignant transformation. Molecular testing revealed heterozygous variants in SMARCA4, APC, and MYBP3, suggesting a permissive background for multiple tumorigenic events. Importantly, all tumors were diagnosed at an early stage and completely resected, thereby enabling curative surgery without the need for adjuvant therapy. This unique presentation underlines the importance of integrated radiological, pathological, and molecular evaluation in patients with multiple synchronous tumors and highlights the role of vigilant follow-up in long-term management.

Keywords: Adrenocortical carcinoma; renal cell carcinoma; mediastinal mature teratoma; SMARCA4 variant; synchronous primary tumors

INTRODUCTION

The occurrence of multiple synchronous primary tumors is uncommon and often poses diagnostic as well as therapeutic challenges. While some cases are associated with well-defined hereditary cancer syndromes such as Li-Fraumeni, Lynch, or von Hippel-Lindau disease, the coexistence of independent tumors outside these classical syndromes is exceedingly rare.[1-3]

Adrenocortical carcinoma (ACC) and renal cell carcinoma (RCC) have occasionally been reported in combination, and mediastinal germ cell tumors are recognized entities, but the simultaneous presence of ACC, RCC, and a mediastinal mature teratoma of comparable size in the same patient has not previously been described.[4-6] Rare reports have described atypical RCC presentations with poor prognosis.[7] In contrast, our patient presented with three synchronous tumors that were completely resected at an early stage, allowing curative surgery without the need for adjuvant therapy.

Molecular profiling revealed heterozygous variants in SMARCA4, APC, and MYBP3, suggesting a permissive genetic

Correspondence: Prof. Ferit Aslan,
Yüksek İhtisas Afiliated Medicalpark Ankara Hospital, Clinic of Medical Oncology, Ankara, Türkiye
E-mail: feritferhat21@gmail.com
ORCID ID: orcid.org/0000-0002-9153-6921

Received: 14.10.2025 **Accepted:** 01.02.2026 **Epub:** 09.03.2026

Cite this article as: Aslan F, Erkılıç B, Arık ŞB, et al. Synchronous adrenocortical carcinoma, renal cell carcinoma, and mediastinal mature teratoma with heterozygous variants in SMARCA4, APC, and MYBP3: a case report. J Oncol Sci. [Epub Ahead of Print]

Available at journalofoncology.org

©Copyright 2026 The Author(s). Published by Galenos Publishing House on behalf of Turkish Society of Medical Oncology.
Licensed under a Creative Commons Attribution-NonCommercial-NoDerivatives 4.0 (CC BY-NC-ND) International License.

background for multiple tumorigenic events. This emphasizes the importance of integrating radiological, pathological, and molecular evaluation in patients with rare tumor associations, where clinical outcomes may vary widely depending on stage and genetic profile.

CASE REPORT

A 46-year-old woman presented with a two-week history of retrosternal chest pain. The physical examination was unremarkable. Thoracic computed tomography (CT) revealed a 6.2 cm anterior mediastinal mass with cystic and necrotic components, while abdominal CT demonstrated two distinct lesions: a 6.5 cm heterogeneously enhancing mass in the upper pole of the right kidney and a 6.7×5.1 cm well-circumscribed adrenal mass (Figure 1).

Fluorodeoxyglucose positron emission tomography/CT confirmed metabolic activity in all three lesions (maximum standardized uptake value: mediastinal 2.19, renal 3.32, adrenal 11.58) without evidence of distant metastasis. A comprehensive endocrine evaluation, including measurements of cortisol, dehydroepiandrosterone sulfate, aldosterone, and catecholamines, as well as an overnight dexamethasone suppression test, revealed no hormonal excess, a finding consistent with a non-functioning ACC. Additionally, tumor markers commonly associated with germ cell tumors—alpha-fetoprotein, beta human chorionic gonadotropin, and lactate dehydrogenase—were within normal limits, supporting the diagnosis of a benign mediastinal teratoma.

The patient underwent right radical nephrectomy, right adrenalectomy, and excision of the mediastinal mass. Histopathological analysis confirmed three independent primary tumors (Figure 2).

- **Renal tumor:** Clear cell RCC, World Health Organization/International Society of Urological Pathology grade 2, confined to kidney, paired box gene 8 and epithelial membrane antigen positive.
- **Adrenal tumor:** ACC, Weiss score 3, inhibin and Melan-A positive, non-functioning.
- **Mediastinal mass:** Mature teratoma composed of gastrointestinal, pancreatic, thymic, and mesenchymal elements, without malignant transformation.

Molecular analysis identified heterozygous variants in SMARCA4, APC, and MYBP3, while no alterations were detected in classical hereditary cancer genes. Importantly, both RCC and ACC were diagnosed at an early stage and were completely resected; therefore, no adjuvant systemic therapy was indicated. The patient has been followed for 20 months after surgery without evidence of recurrence.

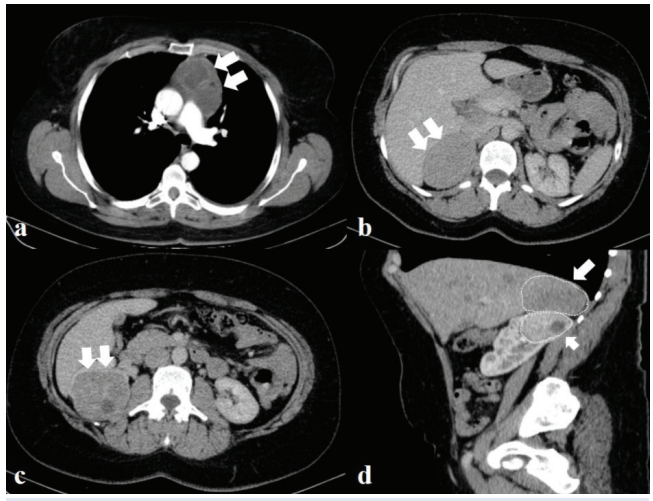

FIGURE 1: Contrast-enhanced computed tomography (CT) images of the same patient demonstrating three distinct masses, (a) An axial thoracic CT image shows a retrosternal mass with heterogeneous enhancement and cystic components (white arrows), (b) Axial abdominal CT image in the portal venous phase shows a homogeneously enhancing right adrenal mass; on dedicated dynamic adrenal CT, the absolute washout was indeterminate (white arrows), (c) Axial abdominal CT image in the portal venous phase demonstrates a heterogeneous right renal mass with residual contrast washout and cystic areas (white arrows), (d) Sagittal multiplanar reconstruction CT image in the arterial phase depicts both the right adrenal and right renal masses in the same plane (white arrows).

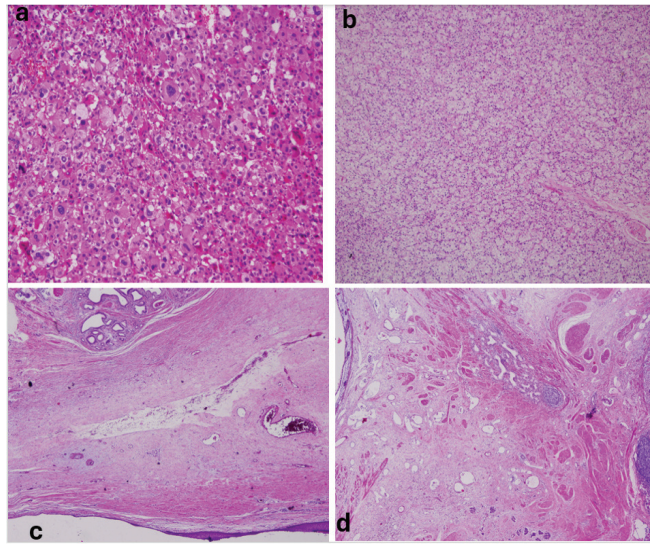

FIGURE 2: Histopathology. (a) Adrenocortical tumor showing marked cellular atypia and pleomorphism without necrosis, mitosis, or vascular invasion (H&E, ×200), (b) Clear cell renal cell carcinoma composed of nests of clear cells with delicate vasculature and minimal nuclear atypia (H&E, ×100), (c) Mature mediastinal teratoma with a cystic component lined by squamous epithelium and subepithelial skeletal muscle fibers (H&E, ×40), (d) Mature mediastinal teratoma containing gastric-type glands and pancreatic tissue elements (H&E, ×40).

H&E: Hematoxylin and eosin

DISCUSSION

The coexistence of three distinct primary tumors in a single patient is exceptionally rare and raises multiple clinical, prognostic, and molecular questions. In the setting of synchronous tumors, outcomes are often worse than for solitary primaries, largely due to diagnostic complexity, increased cumulative tumor burden, or limited therapeutic options. In one large series, the 1-year survival was 56.9%, but the 3-year survival dropped to 20.9%.[8] Other population-based data confirm that synchronous metastases are associated with a poorer prognosis than metachronous ones.[9,10] Case reports also emphasize the rarity and clinical challenges of managing synchronous malignancies.[11]

Demographically, most published reports of synchronous tumors involve middle-aged or older patients, often with a slight male predominance. Younger age has occasionally been associated with better outcomes, whereas unusual presentations in women have also been described in the literatüre.[7,8] These observations underline the importance of age and sex as potential prognostic modifiers in synchronous malignancies.

Clinically, both RCC and ACC were diagnosed at an early stage in our patient. Radical nephrectomy and adrenalectomy achieved complete resection; given the absence of adverse pathological features or hormonal activity, adjuvant systemic therapy was not required. The mediastinal teratoma was also completely excised and confirmed as benign. At 20 months' follow-up, the patient remains recurrence-free, demonstrating that early detection and curative surgery can mitigate the otherwise poor prognosis often reported for synchronous tumors.

From a molecular perspective, heterozygous variants in SMARCA4, APC, and MYBP3 were identified. SMARCA4 is a catalytic subunit of the switch/sucrose non-fermentable chromatin-remodeling complex, and its inactivation has been strongly linked to aggressive tumor biology. In small cell carcinoma of the ovary and thoracic sarcomas, SMARCA4-deficient tumors are associated with poor prognoses; median survival is often below one year.[1,2] In non-small cell lung cancer, SMARCA4 alterations similarly predict shorter overall and progression-free survival.[3,12] Interestingly, some studies suggest that SMARCA4-deficient tumors may respond more favorably to immune checkpoint inhibitors, raising the possibility of immunotherapy as a targeted therapeutic strategy.[12-14]

APC mutations, by contrast, are central to Wnt/β-catenin pathway activation and have been associated with colorectal and adrenal carcinogenesis, often contributing to aggressive tumor biology.[4,5] MYBP3 variants, although less well characterized, have been reported in pan-cancer sequencing efforts and may reflect underlying genomic instability rather than acting as true driver mutations.[6]

In our patient, the coexistence of three synchronous tumors harboring molecular alterations contrasts with the otherwise favorable clinical outcome achieved following complete resection. This underscores the importance of multidisciplinary evaluation: while genetic findings raise concerns for long-term risk, the absence of recurrence after nearly two years highlights that surgical management at an early stage remains the most decisive prognostic factor. Future studies may clarify whether patients with SMARCA4-altered tumors should benefit from closer surveillance or early inclusion in immunotherapy protocols.

CONCLUSION

This case represents an exceptionally rare coexistence of three synchronous primary tumors: RCC, ACC, and a mediastinal mature teratoma. Despite harboring molecular alterations including heterozygous SMARCA4, APC, and MYBP3 variants—changes usually associated with aggressive behavior—the patient achieved a favorable outcome with curative surgery alone. At 20 months' follow-up, she remains disease-free without adjuvant systemic therapy. This case highlights that early-stage diagnosis and complete resection can outweigh adverse molecular markers while emphasizing the importance of vigilant follow-up and the consideration of molecular risk in surveillance planning.

Ethics

Informed Consent: Informed consent was obtained from the patient and the patient's family for publication of the case report.

Footnotes

Authorship Contributions

Surgical and Medical Practices: F.A., Ş.B.A., F.A.Y., E.A., F.Y., H.T., Concept: F.A., B.E., H.T., Design: F.A., B.E., H.T., Data Collection or Processing: F.A., B.E., Ş.B.A., F.A.Y., E.A., H.T., Analysis or Interpretation: F.A., Ş.B.A., F.A.Y., E.A., F.Y., Literature Search: F.A., B.E., Writing: F.A., B.E.

Conflict of Interest: No conflict of interest was declared by the authors.

Financial Disclosure: The authors declared that this study received no financial support.

REFERENCES

1. Witkowski L, Carrot-Zhang J, Albrecht S, et al. Germline and somatic SMARCA4 mutations characterize small cell carcinoma of the ovary, hypercalcemic type. Nat Genet. 2014;46(5):438-443. [Crossref] [PubMed]
2. Yoshida A, Kobayashi E, Kubo T, et al. Clinicopathological and molecular characterization of SMARCA4-deficient thoracic sarcomas with comparison to potentially related entities. Mod Pathol. 2017;30(6):797-809. [Crossref] [PubMed]

3. Naito T, Umemura S, Nakamura H, et al. Clinical impact of SMARCA4 mutations in non-small cell lung cancer. J Thorac Oncol. 2020;15(6):947-955. [Crossref]
4. Assié G, Letouzé E, Fassnacht M, et al. Integrated genomic characterization of adrenocortical carcinoma. Nat Genet. 2014;46(6):607-612. [Crossref] [PubMed]
5. Cancer Genome Atlas Research Network; Kandoth C, Schultz N, Cherniack AD, et al. Integrated genomic characterization of endometrial carcinoma. Nature. 2013;497(7447):67-73. [Crossref] [PubMed] [PMC]
6. Liu J, Lichtenberg T, Hoadley KA, et al; Cancer Genome Atlas Research Network; Hu H. An integrated TCGA pan-cancer clinical data resource to drive high-quality survival outcome analytics. Cell. 2018;173(2):400-416.e11. [Crossref] [PubMed] [PMC]
7. Aslan F, Erkılıç B, Türkmen G, Günaydın E, Hasanov C. Renal cell carcinoma in pregnancy with breast metastasis: a case report and literature review. Cureus. 2025;17(9):e92550. [Crossref] [PubMed] [PMC]
8. Lv M, Zhang X, Shen Y, et al. Clinical analysis and prognosis of synchronous primary malignancies: a single-center study of 1,104 cases. J Surg Oncol. 2017;115(3):282-289. [Crossref]
9. Reboux N, Xu J, Faron M, et al. Incidence and survival in synchronous and metachronous metastases. JAMA Netw Open. 2022;5(9):e2233063. [Crossref]
10. Singnurkar AM, Ma C, Qiu Y, et al. Impact of synchronous cancers on survival in stage I lung cancer: a population-based study. Lung Cancer. 2020;145:12-18. [Crossref]
11. Al Laham O, Elhage J, Alorjani MS, et al. An exceedingly rare simultaneous incidental occurrence of synchronous malignancies. Int J Surg Case Rep. 2022;92:106823. [Crossref]
12. Cancer Genome Atlas Research Network. Comprehensive molecular profiling of lung adenocarcinoma. Nature. 2014;511(7511):543-550. Erratum in: Nature. 2014;514(7521):262. Rogers, K [corrected to Rodgers, K]. Erratum in: Nature. 2018;559(7715):E12. [Crossref] [PubMed] [PMC]
13. Schrock AB, Zhu VW, Hsieh WS, et al. Receptor tyrosine kinase fusions and SMARCA4 mutations as potential targets for immunotherapy in NSCLC. J Thorac Oncol. 2019;14(10):1887-1896. [Crossref]
14. Henon C, Blay JY, Massard C, et al. Efficacy of immune checkpoint inhibitors in SMARCA4-deficient thoracic tumors: a multicenter retrospective study. Ann Oncol. 2021;32(6):702-710. [Crossref]